

**Platelet-Rich Plasma
From Basic Science to Clinical Applications**

Timothy E. Foster, Brian L. Puskas, Bert R. Mandelbaum, Michael B. Gerhardt and Scott A. Rodeo

Am J Sports Med 2009 37: 2259. DOI: 10.1177/0363546509349921

OBJETIVO

Recientemente ha incrementado el interés del uso del PRP en medicina deportiva tras haberse utilizado en cirugía durante 2 décadas. El PRP contiene factores de crecimiento y proteínas bioactivas que aceleran la reparación de tendones, ligamentos, músculos y hueso.

Antes de adoptar el PRP en la práctica de la medicina deportiva es importante valorar la evidencia científica de su eficacia y seguridad. Este artículo se centra en el estudio de la base científica del PRP y sus aplicaciones

Factores Bioactivos en el PRP

El PRP puede mejorar la regeneración al aportar factores de crecimiento y citoquinas de los gránulos contenidos en sus plaquetas: Factor de crecimiento transformante- β (TGF- β), factor de crecimiento derivado de plaquetas (PDGF), factores de crecimiento tipo insulina (IGF-I, IGF-II), factor de crecimiento fibroblástico (FGF), factor de crecimiento epidérmico, factor de crecimiento vascular endotelial (VEGF). Estos agentes juegan un papel importante en la proliferación y diferenciación celular, quimiotaxis y angiogénesis.

Además estos gránulos contienen otras sustancias como serotonina, histamina, dopamina, calcio y adenosina, que toman parte en los aspectos biológicos de la reparación tisular

Efectos del PRP sobre tejidos blandos

Las citoquinas y otros factores liberados por el PRP influyen en los procesos metabólicos que suceden en la reparación del tejido musculo-esquelético, incluyendo tendones, músculos y ligamentos

APLICACIONES CLÍNICAS ACTUALES

1. Tendinopatías crónicas: *Tendinopatía de codo/Epicondilitis Lateral/ Codo de tenista; Tendinopatía del tendón de Aquiles; Fascitis plantar; Tendinopatía Patelar*
2. Regeneración ósea: *Osteoartritis.*
3. Lesiones ligamentosas agudas
4. Lesiones musculares
5. Uso intraoperatorio del PRP: *Artroplastia total de rodilla; Reconstrucción del ligamento cruzado anterior; Reparación del tendón de Aquiles; Reparación del manguito de los rotadores; Reparación del cartilago articular*
6. El PRP se ha utilizado también para crear una respuesta zonal en casos de epicondilitis lateral en el codo, y fascitis plantar. Recientemente se ha utilizado esta tecnología en el tratamiento de lesiones ligamentosas agudas en medicina deportiva para acelerar la recuperación

Platelet-Rich Plasma. From Basic Science to Clinical Applications. Timothy E. Foster, Brian L. Puskas, Bert R. Mandelbaum, Michael B. Gerhardt and Scott A. Rodeo. *Am J Sports Med* 2009 37: 2259. DOI: 10.1177/0363546509349921

CONCLUSIONES

- El PRP es un material autólogo, de fácil administración, con excelente perfil de seguridad
- Los principales beneficios del PRP se basan en una aceleración en la recuperación de tejidos blandos, con una baja probabilidad de potencial rechazo, y con una preparación sencilla, rápida y barata en comparación con la recogida de células mesenquimales.
- Sin embargo también existen limitaciones o puntos de mejora, como la falta de definición de la dosis óptima de PRP; además existen controversias acerca del efecto del PRP sobre la proliferación y diferenciación celular de las células mesenquimales en células de otra serie distinta de la deseada, aunque no exista evidencia científica de que esto pueda ocurrir
- El PRP y productos derivados han sido y son utilizados con conocidos beneficios aplicables a la medicina deportiva. El uso de PRP en medicina deportiva no está exento de ciertas controversias en algunas agencias reguladoras del sistema de antidopaje.

CONFIDENCIAL

The American Journal of Sports Medicine

<http://ajs.sagepub.com/>

Platelet-Rich Plasma

Timothy E. Foster, Brian L. Puskas, Bert R. Mandelbaum, Michael B. Gerhardt and Scott A. Rodeo

Am J Sports Med 2009 37: 2259

DOI: 10.1177/0363546509349921

The online version of this article can be found at:
<http://ajs.sagepub.com/content/37/11/2259>

Published by:



<http://www.sagepublications.com>

On behalf of:



American Orthopaedic Society for Sports Medicine

Additional services and information for *The American Journal of Sports Medicine* can be found at:

Email Alerts: <http://ajs.sagepub.com/cgi/alerts>

Subscriptions: <http://ajs.sagepub.com/subscriptions>

Reprints: <http://www.sagepub.com/journalsReprints.nav>

Permissions: <http://www.sagepub.com/journalsPermissions.nav>

Platelet-Rich Plasma

From Basic Science to Clinical Applications

Timothy E. Foster,^{*†} MD, Brian L. Puskas,[†] MD, Bert R. Mandelbaum,[‡] MD,
Michael B. Gerhardt,[‡] MD, and Scott A. Rodeo,[§] MD

From [†]Boston University School of Medicine, Boston, Massachusetts,

[‡]Santa Monica Orthopaedic and Sports Medicine Group, Santa Monica,

California, and the [§]Hospital for Special Surgery, New York, New York

Platelet-rich plasma (PRP) has been utilized in surgery for 2 decades; there has been a recent interest in the use of PRP for the treatment of sports-related injuries. PRP contains growth factors and bioactive proteins that influence the healing of tendon, ligament, muscle, and bone. This article examines the basic science of PRP, and it describes the current clinical applications in sports medicine. This study reviews and evaluates the human studies that have been published in the orthopaedic surgery and sports medicine literature. The use of PRP in amateur and professional sports is reviewed, and the regulation of PRP by antidoping agencies is discussed.

Keywords: platelet-rich plasma (PRP); growth factors

Research into the biology of bone, ligament, and tendon healing has led to the development of a variety of products designed to help stimulate biologic factors and promote healing. The use of the autologous and recombinant products is a rapidly growing field of orthopaedics focusing on manipulating growth factors and secretory proteins to maximize the healing of bone and soft tissues. Despite their clinical use, many of these products have not been studied using rigorous scientific standards.

Platelet-rich plasma (PRP) is an example of one such autologous product that has been utilized and studied since the 1970s. Platelet-rich plasma has been used clinically in humans for its healing properties attributed to the increased concentrations of autologous growth factors and secretory proteins that may enhance the healing process on a cellular level. The hope is that PRP enhances the recruitment, proliferation, and differentiation of cells involved in tissue regeneration. In the literature, PRP-related products, also known as PRP, platelet-rich concentrate, platelet gel, preparation rich in growth factors (PRGF), and platelet releasate, have been studied with *in vitro* and *in vivo* experiments in the fields of maxillofacial surgery and general surgery.⁶⁴ More recently, PRP's role in muscle and tendon healing has been investigated within the orthopaedic literature and its use is becoming more familiar to the general public.⁵ A February 2009 article in *The New York Times* raised the public awareness of PRP by

detailing the use of PRP to treat an injured Pittsburgh Steelers football player before the 2009 Superbowl.⁷⁹

Although there are numerous basic science studies, animal studies, and small case reports regarding PRP-related products, there are only a few controlled, clinical studies that provide a high level of medical evidence regarding the potential benefits of PRP. The number of participants in the studies is typically small, and the majority of studies are underpowered. In sports medicine and orthopaedic surgery, the use of PRP and the studies examining its effects have not used standardized techniques, and the majority are anecdotal studies based on small case series (Level 4 evidence). Before adopting PRP into a sports medicine practice, it is important to assess the evidence in the literature that supports its safety and efficacy. This article will focus on the basic science and clinical applications of PRP. It will also examine the medical literature involving the use of PRP in orthopaedic surgery and other surgical specialties.

THE BASIC SCIENCE OF PRP

Definition of PRP

Platelets are small, nonnucleated bodies in peripheral blood that are known primarily for their role in hemostasis. Platelets contain a number of proteins, cytokines, and other bioactive factors that initiate and regulate basic aspects of wound healing. Normal platelet counts in blood range from 150 000/ μ L to 350 000/ μ L. Plasma is the fluid portion of blood and contains clotting factors and other proteins and ions. Platelet-rich plasma, with a platelet concentration of at least 1 000 000 platelets/ μ L in 5 mL of plasma, is associated with the enhancement of healing.⁶¹ Platelet-rich plasma contains a 3- to 5-fold increase in growth factor concentrations. Greater platelet concentrations have

*Address correspondence to Timothy E. Foster, MD, Co-Director, Sports Medicine, Boston University School of Medicine, 720 Harrison Avenue, Suite 805, Boston, MA 02118 (e-mail: mdsportsmed@aol.com).

No potential conflict of interest declared.

TABLE 1
Growth Factors Identified Within Platelet-Rich Plasma and Their Physiologic Effect^a

Factor	Target Cell/Tissue	Function
PD-EGF	Blood vessel cells, outer skin cells Fibroblasts, and many other cell types	Cell growth, recruitment Differentiation, skin closure Cytokine secretion
PDGF A + B	Fibroblasts, smooth muscle cells, chondrocytes, osteoblasts, mesenchymal stem cells	Potent cell growth, recruitment Blood vessel growth, granulation Growth factor secretion; matrix formation with BMPs (collagen and bone)
TGF- β 1	Blood vessel tissue, outer skin cells Fibroblasts, monocytes TGF gene family includes the BMPs Osteoblasts—highest levels of TGF- β r	Blood vessel (\pm), collagen synthesis Growth inhibition, apoptosis (cell death) Differentiation, activation
IGF-I, II	Bone, blood vessel, skin, other tissues Fibroblasts	Cell growth, differentiation, recruitment Collagen synthesis with PDGF
VEGF, ECGF	Blood vessel cells	Cell growth, migration, new blood vessel growth Anti-apoptosis (anti-cell death)
bFGF	Blood vessels, smooth muscle, skin Fibroblasts, other cell types	Cell growth Cell migration, blood vessel growth

^aPD-EGF, platelet-derived epidermal growth factor; PDGF, platelet-derived growth factor; BMP, bone morphogenetic protein; TGF, transforming growth factor; IGF, insulin-like growth factor; VEGF, vascular endothelial growth factor; ECGF, endothelial cell growth factor; bFGF, basic fibroblast growth factor.

not been shown to further improve healing, although a number of variables affect the biologic activity of various PRP preparations.

A number of terms have been loosely used to refer to preparations that isolate and concentrate platelets, such as "plasma rich in platelets." The term "platelet concentrate" has been used, but is inaccurate because this implies a solid composition of platelets without plasma, which would not clot. The term "platelet gel" has also been used, but this is also incorrect because the gel does not contain the cell adhesion molecules present in clot. Platelet-rich plasma differs from "fibrin glue" because the clot in PRP contains only the same concentrations of fibrin as a normal blood clot.

Bioactive Factors in PRP

Platelet-rich plasma can potentially enhance healing by the delivery of various growth factors and cytokines from the α -granules contained in platelets. The basic cytokines identified in platelets include transforming growth factor- β (TGF- β), platelet-derived growth factor (PDGF), insulin-like growth factor (IGF-I, IGF-II), fibroblast growth factor (FGF), epidermal growth factor, vascular endothelial growth factor (VEGF), and endothelial cell growth factor. These cytokines play important roles in cell proliferation, chemotaxis, cell differentiation, and angiogenesis (Table 1). A particular value of PRP is that these native cytokines are all present in "normal" biologic ratios. In contrast, exogenous cytokines such as bone morphogenetic protein (BMP) are produced by recombinant technology and are delivered in high doses using a carrier vehicle. Because healing is a highly complex process, there are distinct limitations to the ability of single-factor therapy (ie, delivery of an exogenous growth factor) to improve tissue healing.

Bioactive factors are also contained in the dense granules in platelets. The dense granules contain serotonin, histamine,

dopamine, calcium, and adenosine. These non-growth factors have fundamental effects on the biologic aspects of wound healing. The 3 stages of healing are inflammation, proliferation, and remodeling. The inflammatory stage begins with tissue injury; consequently, platelets are stimulated to aggregate and secrete growth factors, cytokines, and hemostatic factors critical in the early stages of the intrinsic and extrinsic pathways of the clotting cascade. Histamine and serotonin are released by platelets and both function to increase capillary permeability, which allows inflammatory cells greater access to the wound site and activates macrophages.^{10,56} Polymorphonuclear leukocytes migrate toward the area of inflammation and, soon thereafter, cells begin to proliferate while fibroblasts help form a ground substance. Adenosine receptor activation modulates inflammation during wound healing (Tables 2 and 3).

The platelets in PRP are delivered in a clot, which contains several cell adhesion molecules including fibronectin, fibrin, and vitronectin. These cell adhesion molecules play a role in cell migration, and thus also add to the potential biologic activity of PRP. The clot itself can also play a role in wound healing by acting as conductive matrix or "scaffold" upon which cells can adhere and begin the wound-healing process.

Formulation of PRP

Platelet-rich plasma can only be made from anticoagulated blood. It cannot be made from clotted whole blood because platelets become part of the clot. Platelet-rich plasma also cannot be made from serum. Serum is the clear liquid part of the blood that remains after blood cells and clotting proteins have been removed; the serum contains very few platelets. Preparation of PRP begins by addition of citrate to whole blood to bind the ionized calcium and inhibit the

TABLE 2
Bioactive Molecules Found in the α -Granules of Platelets^a

General Activity Categories	Specific Molecules	Biologic Activities
Growth factors	TGF- β	Promotes matrix synthesis
	PDGF	Chemoattraction, cell proliferation
	IGF-I, II	Cell proliferation, maturation, bone matrix synthesis
	FGF	Angiogenesis, fibroblast proliferation
	EGF	Cell proliferation
	VEGF	Angiogenesis
	ECGF	Endothelial cell proliferation, angiogenesis
Adhesive proteins	Fibrinogen	Blood clotting cascade (fibrin clot formation)
	Fibronectin	Binds to cell-surface integrins, affecting cell adhesion, cell growth, migration, and differentiation
	Vitronectin	Cell adhesion, chemotaxis
	Thrombospondin-1	Inhibition of angiogenesis
Clotting factors	Factor V, factor XI, protein S, antithrombin	All play a role in thrombin activation and eventual fibrin clot formation
Fibrinolytic factors	Plasminogen	Plasmin production (leads to fibrinolysis)
	Plasminogen activator inhibitor	Regulation of plasmin production
	α -2 antiplasmin	Inactivation of plasmin
Proteases and antiproteases	TIMP-4	Regulation of matrix degradation
	Metalloprotease-4	Matrix degradation
Basic proteins	α 1-antitrypsin	Inhibits a wide variety of proteases and enzymes
	Platelet factor 4	Inhibition of angiogenesis
	β -thromboglobulin	Platelet activation, inhibition of angiogenesis
Membrane glycoproteins	Endostatins	Inhibitors of endothelial cell migration and angiogenesis
	CD40 ligand	Inflammation, synthesis of interleukins, and integrin production; platelet endothelial cell adhesion, cell signaling, modulation of integrin activation molecule-1 (PECAM-1) on leukocytes
	P-selectin	Vascular cell adhesion molecule, aids in binding and recruitment of leukocytes to inflamed tissue

^aTGF, transforming growth factor; PDGF, platelet-derived growth factor; IGF, insulin-like growth factor; FGF, fibroblast growth factor; EGF, epidermal growth factor; VEGF, vascular endothelial growth factor; ECGF, endothelial cell growth factor; TIMP-4, tissue inhibitor of metalloprotease-4.

clotting cascade. This is followed by one or two centrifugation steps. The first centrifugation step separates the red and white blood cells from plasma and platelets. Red blood cells (7 μ m in diameter) and white blood cells (7-15 μ m in diameter) are much larger than platelets (2 μ m in diameter); these cells separate from the plasma and platelets. The second centrifugation step further concentrates the platelets, producing the PRP separate from platelet-poor plasma.

The PRP must then be clotted to allow for delivery to the desired site. Some commercially available systems use bovine thrombin to activate the clotting mechanism. An important point is that clotting leads to platelet activation, resulting in release of the growth factors from the α -granules, otherwise known as degranulation. Approximately 70% of the stored growth factors are released within 10 minutes, and nearly 100% of the growth factors are released within 1 hour.⁶¹ Small amounts of

growth factors may continue to be produced by the platelet during the rest of its lifespan (8 to 10 days).

The use of bovine thrombin to activate the clotting mechanism and to induce platelet activation can lead to complications associated with formation of antibodies against the bovine thrombin. This is a rare but potentially serious complication that can result in an immune-mediated coagulopathy. Thrombin-activated clots also demonstrate significant retraction.

An alternative system to delay the release of growth factors is possible through the creation of a "platelet-rich fibrin matrix" (PRFM, Cascade Platelet Rich Plasma Therapy, MTF Sports Medicine, Edison, New Jersey).¹⁸ This is done by addition of calcium chloride (CaCl₂) to initiate the formation of autogenous thrombin from prothrombin. The CaCl₂ is added during the second centrifugation step and results in formation of a dense fibrin matrix. Intact platelets are subsequently trapped in the fibrin

TABLE 3
Bioactive Molecules Found in the Dense
Granules of Platelets^a

Specific Molecules	Biologic Activities
Serotonin	Vasoconstriction, increased capillary permeability, macrophage attraction
Histamine	Increased capillary permeability, attract and activate macrophages
Dopamine	Regulation of heart rate and blood pressure, neurotransmitter
ADP	Promotes platelet aggregation
ATP	Participates in platelet response to collagen
Ca ⁺⁺	Cofactor for platelet aggregation and fibrin formation
Catecholamines	Sympathomimetic hormones released by the adrenal glands in response to stress

^aADP, adenosine diphosphate; ATP, adenosine triphosphate.

matrix. This system results in only a small amount of thrombin and thus minimizes platelet activation. The result is that the platelets release growth factors slowly over a 7-day period. The fibrin matrix itself may also contribute to healing by providing a conductive scaffold for cell migration and new matrix formation.

An alternative method to activate the platelets is to use type I collagen. Collagen has been found to be equally effective as thrombin in stimulating the release of PDGF and VEGF in a study that mixed soluble type I collagen with PRP to create a collagen-PRP gel.³⁴ Clots formed using type I collagen also had significantly less ($P < .003$) retraction than clots formed using bovine thrombin. Further study is required to determine if tendon collagen in vivo can induce clotting of unactivated PRP and lead to platelet activation. Relying on collagen to activate PRP in vivo allows injection of unactivated PRP, which can be done using a small-gauge needle.

Effects of PRP on Soft Tissues

Connective tissues, such as tendon, ligament, and muscle, heal through the 3 phases: inflammation, proliferation, and remodeling. Various cytokines are active during each of these phases of wound healing. Cytokines play a fundamental role in wound healing by binding to transmembrane receptors on local and circulating cells, initiating intracellular signaling that ultimately affects nuclear gene expression. The result is the expression of proteins that regulate cell proliferation, cell chemotaxis, angiogenesis, cellular differentiation, and extracellular matrix production. The cytokines and other bioactive factors released from PRP are known to affect these basic metabolic processes in soft tissues of the musculoskeletal system including tendon, ligament, and muscle.

Effects of PRP on Tendon. When considering the role of PRP in tendon healing, it is important to distinguish treatment of acute tendon injury from chronic tendinosis. The

biologic aspects of tendon healing and remodeling may be quite different between these 2 clinically distinct situations. Several recent studies have clearly shown that PRP positively affects gene expression and matrix synthesis in tendon and tendon cells. Cell proliferation and total collagen production is increased in human tenocytes cultured in PRP with slightly increased expression of matrix-degrading enzymes matrix metalloproteinase (MMP)-1 and MMP-3.²⁶ Equine flexor digitorum superficialis tendon explants cultured in PRP showed enhanced gene expression of type I collagen, type III collagen, and cartilage oligomeric matrix protein with no concomitant increase in the catabolic molecules MMP-3 and MMP-13.⁷⁸ In vivo, a platelet concentrate injected percutaneously into the hematoma 6 hours after creation of defect in a rat Achilles tendon resulted in increased tendon callus strength and stiffness.⁷ A recent study showed that PRP injected into a patellar tendon injury site in a chimeric rat expressing green fluorescent protein in circulating cells and bone marrow cells resulted in increased recruitment of circulation-derived cells to the injury site, with concomitant increased collagen production.⁴⁶

Effects of PRP on Muscle. Several cytokines contained in PRP have a positive effect on muscle healing. For example, basic FGF (bFGF) and IGF-I improved muscle healing in a gastrocnemius muscle laceration model in mice. Muscles treated with IGF-I and bFGF showed improved healing and significantly increased fast-twitch and tetanus strength.⁶⁵ Autologous conditioned serum injected at 2, 24, or 48 hours after injury in a mouse gastrocnemius contusion injury model resulted in accelerated satellite cell activation and increased diameter of regenerating myofibers.⁸⁵

Basic Science Issues That Require Further Study

A number of important questions remain about the basic biologic mechanisms of PRP. Further information is required to examine the differential effects on acutely injured tendon versus degenerative tendon. The underlying cellular and molecular processes are quite different between these two disparate clinical conditions. In the treatment of acutely injured soft tissue (tendon, ligament, or muscle), the best time to inject PRP must be determined. The biologic milieu changes as healing progresses, and thus the effects of cytokines may be very different at varying times after injury. There may even be the potential to exacerbate inflammation (and thus pain) in the setting of acute injury. In addition to determining the best time for PRP injection, the effect of serial injections should be explored. The kinetics of cytokine release from various PRP preparations needs further study, as this may ultimately determine the best time for injection for a given PRP formulation. Lastly, the effect of local tissue pH on PRP activity needs further study as there are some preliminary data that cytokine release from PRP is pH-dependent.⁶⁴

CURRENT CLINICAL APPLICATIONS

The literature is replete with studies documenting the safe and efficacious use of PRP in a wide variety of fields. A

number of animal studies, case reports, and small case series in the oral and maxillofacial surgery, otolaryngology, plastic surgery, and general surgery literature have examined the role of PRP in various clinical settings.¹¹ These include human case studies supporting the use of PRP-related products, suggesting an overall improvement in soft tissue healing. Likewise, within the oral and maxillofacial surgery literature, there are other small human case reports that argue there is little benefit from using PRP to promote healing or osteogenesis.^{23,33,72} In many cases, the terms autogenous platelet concentrate, platelet gel, and fibrin glue are used as synonyms for PRP; however, as defined at the beginning of this article, they are distinct platelet-related products.

Many of these studies claim excellent outcomes but are at best limited case series; consequently, it is difficult to draw conclusions from these case reports that may or may not have controls, have small sample sizes, and do not define a standardized preparation of PRP. This makes it hard to interpret any of the results.⁶⁰ Standardized dosing and composition of PRP is necessary in order to compare the data from different studies. Unfortunately, most of these human clinical studies lack statistical significance because of small sample sizes and a paucity of randomized controlled trials. Efforts are currently underway designing clinical studies that will help further delineate the effects of PRP.

Currently, the majority of orthopaedic applications for PRP can be grouped into 1 of 4 categories: chronic tendinopathies, acute ligamentous injuries, muscle injuries, and intraoperative augmentation. Historically, the focus has been on intraoperative use, such as in the use of platelet-derived products (fibrin sealants, platelet gels, etc) for sealing wounds following total knee replacement in an effort to minimize blood loss and promote wound healing.^{12,38} Platelet-rich plasma has been used to induce a local healing response in conditions such as lateral epicondylitis and plantar fasciitis.⁶⁶ Most recently, orthopaedic surgeons have applied this technology to the treatment of acute ligamentous injuries in an effort to expedite healing and return to play.⁷⁹ The application of a new technology in medicine is often met with significant enthusiasm.⁷³ This may be especially true in sports medicine when the patients are often elite athletes. The indications for the use of the technology often outpace the basic science and clinical studies that validate the technology's efficacy.

Recently published human clinical orthopaedic studies of PRP are summarized in Table 4.

Chronic Tendinopathy

Elbow Tendinopathy / Lateral Epicondylitis. A PRP injection can be used for patients with refractory lateral epicondylitis of the elbow who have failed conservative treatment including physical therapy, a counter-force brace, and corticosteroid injections. It is recommended that imaging studies including either MRI or ultrasound should confirm extensor carpi radialis brevis tendinopathy. Postinjection protocol includes standard rehabilitation for eccentric

strengthening and functional progressions with a gradual return to activities over 6 to 8 weeks. It is not necessary to immobilize the elbow after the injection. The criteria for return to sports may include painless full range of motion with no localized pain or tenderness.

Mishra and Pavelko⁶⁶ evaluated a series of 140 patients with chronic lateral epicondylar elbow pain. Of those patients, 20 met the inclusion criteria and were offered PRP injection as an alternative to surgery. Fifteen patients underwent PRP injection and 5 patients served as controls by undergoing local anesthetic injection only. The patients undergoing PRP therapy were noted to have 60% improvement at 8 weeks, 81% at 6 months, and 93% at final follow-up (range, 12-38 months). At 8 weeks, 3 of the 5 patients in the control group sought treatment outside the study or formally withdrew from the study and limiting comparisons. Therefore, the final outcome data reflects only the patients who were treated with PRP. At the final follow-up of these patients (range 12-38 months), 93% were completely satisfied with the treatment, 94% (range 90-100%) of PRP-treated patients were able to return to work and sports, and 99% were able to return to activities of daily living. No adverse events or complications were reported. This study has significant design flaws; the sample size is small and the attrition rate approaches 60%. However, it is one of the few studies performed in a prospective fashion and includes a control group.

In 2003, Edwards and Calandruccio²⁶ reported a 79% success rate in treating a group of patients with refractory chronic epicondylitis. Twenty-two of the 28 patients were reported to be pain-free following autologous blood injection therapy. Edwards and Calandruccio injected whole blood that had not been centrifuged, which is different than the preparation for PRP. No adverse events and no recurrences were reported. However, the authors do not comment on the discomfort level at the site of injection in a large portion of their patients in the immediate period following the autologous blood injection. This is a Level 4 study with a small sample size and no control group; consequently, it is difficult to draw definitive conclusions.

Achilles Tendinopathy. The theoretical explanation for tendon injuries suggests a continuum of events, including hypovascularity and repetitive microtrauma, resulting in localized tendon degeneration and weakness. The ultimate result may be rupture if it is continually subjected to loads that exceed the tendon's physiologic capacity. Based on this model, the introduction of PRP is hypothesized to reverse the effects of tendinopathy by stimulating revascularization and enhancing healing at a microscopic level.⁴ It is important to recognize that Achilles tendinopathy may have different clinical manifestations and may require varying treatments. Achilles tendon pathology can be classified into 3 different categories: paratendinitis, paratendinitis with tendinosis, and pure tendinosis.⁴

Paratendinitis involves inflammation only in the paratenon, regardless of whether it is lined by synovium. The paratenon thickens, and adhesions may form between the paratenon and the tendon. Platelet-rich plasma injection for this disorder has not been described. However, patients will rarely present with isolated paratendinitis

¹References 1, 2, 13, 16, 24, 28, 30, 39, 43, 47, 48, 50, 51, 58, 59, 62, 82.

TABLE 4
Published Human Clinical Orthopaedic PRP Studies^a

Authors (Year)	Diagnosis	Design	Level of Evidence	Results	Critiques
Mishra et al ⁶⁶ (2006)	Chronic elbow tendinitis	Cohort, 15 patients injected with PRP	Level 2, 5 controls	Decreased pain at 2 years (measured by visual analog pain score)	Small sample size, not randomized, not blinded, 3 of 5 controls left study at 8 weeks, underpowered
Sánchez et al ⁷⁶ (2007)	Achilles tear healing	Case-control, 6 repairs with PRP	Level 3, 6 matched retrospective controls	Improved ROM and early return to activity with PRP by ± 4 -7 weeks	Small sample size, not randomized, underpowered
Savarino et al ⁷⁷ (2006)	Bone healing in varus HTOs for genu varus	Randomized case-control, 5 patients with bone grafted with bone chips and PRP	Level 4, 5 controls bone-grafted without PRP	No functional or clinical difference; histology shows increased amounts of osteoid and osteoblasts in PRP group	Small sample size, underpowered
Dallari et al ²² (2007) ^b	Bone healing in varus HTOs for genu varus	Prospective randomized control: group A, bone chips with platelet gel (n = 11); group B, bone chips, BMC, and platelet gel (n = 12)	Level 1, 10 controls treated with bone chips only	Biopsies at 6 weeks after surgery showed increased osteoid and osteoblasts in groups A and B; radiographic differences decreased with time; no clinical difference at 1 year among all groups	Underpowered
Kitoh et al ⁴⁹ (2007)	Bone healing in distraction osteogenesis for limb lengthening and short stature	Retrospective, comparison case control; at 3 weeks, patients injected with expanded BMC with or without PRP (n = 32 bones)	Level 3, 60 bones in retrospective control group (high % of congenital etiologies vs PRP group)	Average healing in BMC + PRP was 34 ± 4 d/cm; control group average was 73.4 ± 27 d/cm (P = .003)	Small sample size, not randomized, confounding bias (BMC or PRP working), underpowered
Carreon et al ¹⁷ (2005) ^b	Bone healing in instrumented posterolateral spinal fusions	Retrospective cohort study to evaluate rates of nonunion in patients (n = 76) with autologous iliac bone graft augmented with platelet gel	Level 4, case-control group of 76 randomly selected patients who were matched and grafted with autogenous iliac bone graft with no platelet gel	Nonunion rate in platelet gel group was 25%; 17% in control group (P = .18, not significant)	Small sample size, not randomized, retrospective study, underpowered
Sánchez et al ⁷⁶ (2009) ^b	Bone healing in nonunions	Retrospective, case series; 16 nonhypertrophic nonunions treated with either surgery and PRGF or percutaneous injections of PRGF to stimulate (n = 3) without surgery	Level 4, no control group	84% healed after surgical treatment; unclear if PRGF made a difference	Small sample size, not randomized, retrospective study, underpowered

^aPRP, platelet-rich plasma; ROM, range of motion; HTO, high tibial osteotomy; BMC, bone marrow cells; PRGF, preparation rich in growth factors.

^bStudies describe PRP with different terminology such as PRGF or platelet gel when they are using a product consistent with the term PRP.

and some authors believe that this process is the predecessor to tendinosis.⁴

Paratendinitis with tendinosis involves not only inflammation of the paratenon, but also a degenerative change within the substance of the tendon. Kvist et al⁶³ and Puddu et al⁷¹ have described the gross characteristics of this

condition as a thickening, softening, and yellowish discoloration of the tendon found at the time of surgery. As in tendinitis, pain also is commonly noted because of the inflammatory process.

Pure tendinosis often appears as a nodule that is mobile with plantarflexion.⁴ Histopathologic changes such as

mucoid degeneration, lipomatous infiltration, and calcifying tendinopathy have been noted at the time of surgical repair. Platelet-rich plasma has been advocated for use in chronic Achilles tendinopathy. Based on the gross and histologic properties of Achilles tendinosis, an opportunity theoretically exists for improvement by injecting PRP in an effort to stimulate angiogenic infiltration and remodeling by tenocytes. Ultimately, the use of PRP may lead to an improvement in symptoms and increased function in the group of patients suffering from tendinosis with or without paratendinitis.

Patients with refractory Achilles tendinopathy who have failed physical therapy and multiple modalities of conservative treatment are candidates for PRP injection. The physical examination findings should confirm the presence of Achilles tendinopathy and be corroborated with imaging studies. Some clinicians have advocated the use of ultrasound guidance for needle localization and confirmation of the PRP aliquot directly into the affected area.

Immediately after the injection, the patient is protected with a brace and is removed from athletic activity. To enhance tendon healing, an immediate protocol of active and active-assisted range of motion strictly in the plantar flexion-dorsiflexion plane is initiated. The patient gradually progresses with a standard protocol for strength and functional recovery. In our opinion, a gradual return to activities over 6 to 8 weeks is recommended depending on the size and severity of the lesion.

Plantar Fasciitis. The use of PRP in the foot has only been studied for the treatment of chronic refractory plantar fasciitis. Barrett and Erredge⁸ reported on a small series of patients with chronic plantar fasciitis. The diagnosis was confirmed by ultrasound, and the study participants underwent a "washout" period for 90 days prior to PRP injection in which brace wear, nonsteroidal anti-inflammatory drugs (NSAIDs), and corticosteroid injection were prohibited. The PRP injection was administered into the medial plantar fascia with ultrasound guidance. Six of 9 patients achieved complete symptomatic relief after 2 months. After 2 months, the failure group was offered the option of a second PRP injection. One of the 3 unsuccessful patients eventually achieved complete resolution of symptoms after the second PRP injection. Overall, 77.9% of patients had complete resolution symptoms at 1 year. This study was limited by its small sample size and lack of a control group.

Patients with refractory plantar fasciitis who have failed physical therapy and multiple conservative modalities including orthoses, NSAIDs, and corticosteroid injections may be candidates for PRP injections. An MRI or ultrasound study may confirm the diagnosis; however, imaging studies are of uncertain value in the diagnosis of plantar fasciitis. It is unknown whether PRP is beneficial for patients with tears of the plantar fascia because there are no data on this specific problem at the time of this publication. The postinjection protocol should include immediate weightbearing and a standard rehabilitation program for strength and functional progress. A gradual return to activities over 6 to 8 weeks is recommended, with a more gradual modified training schedule for running athletes.

Patellar Tendinopathy. Patellar tendinopathy is distinguished from other patellar tendon ailments by the

presence of intrasubstance changes demonstrated on ultrasound or MRI.^{27,32} Patellar tendinosis most commonly involves the proximal bone-tendon junction. The intrasubstance changes within the tendon histologically are described as angiofibroblastic hyperplasia.^{31,70} The origin of patellar tendinosis is thought to be due to extrinsic factors such as intensity and duration of training, training surfaces, footwear, and equipment. More recent studies focus on intrinsic factors such as patellar impingement, malalignment, and muscle imbalance, which may predispose a jumping athlete to patellar tendinosis.⁵²

Chronic patellar tendinopathy, also commonly referred to as jumper's knee, represents a significant problem in the athlete. There are very few modalities that have been shown to expedite healing time; the current treatment relies on physical therapy and relative rest from sports participation. Platelet-rich plasma therapy is thought to be an adjunctive solution in an effort to accelerate healing in this chronic disorder.

Taylor et al⁸³ conducted an animal study in an effort to demonstrate the safety of autologous blood injections. An autologous whole blood product, without centrifugation as is performed with PRP, was injected into the patellar tendon of New Zealand White rabbits. A histologic analysis was performed at 6 and 12 weeks after injection; the results suggest a robust angiogenic response and no abnormal histologic markers. There were no adverse events and it was concluded that autologous blood product injection into the patellar tendon posed little if any risk both locally and systemically.

Kajikawa et al⁴⁵ more recently examined the effects of PRP injection into the patellar tendon of rats and concluded that this is a safe and potentially effective treatment modality for tendon healing. Histologic analysis of the tendon after injection demonstrated increased levels of types I and III collagen and macrophages, which is consistent with repair and remodeling of the tendon. There were no local adverse events noted.

In our experience, patellar tendinosis in humans often resolves with prolonged conservative treatment that focuses on quadriceps stretching, achieving quadriceps-hamstring muscle balance, ice, cross-friction massage, and local modalities. However, it is not uncommon for patients to continue to exhibit pain and disability despite a prolonged course of conservative care. In the athlete, when the disability affects the ability to train and/or play at the level of desired performance, other options are considered. Traditionally, surgical intervention is the next step in the treatment algorithm. Surgical debridement of the mucoid degeneration may improve the functional capacity of the patient; however, the surgical procedure is invasive and associated with several months of rehabilitation in our experience. Before surgical intervention, PRP offers an alternative treatment option in the patient who has failed conservative measures.

When considering PRP intervention, it is critical to distinguish patellar tendinosis from other common causes of anterior knee pain, particularly in the adolescent athlete. There are currently no prospective, randomized studies to help guide treatment of patellar tendinopathy with PRP. The clinician must distinguish between patellar tendinopathy and other clinical entities such as Sinding-Larsen-Johansson

disease or Osgood-Schlatter disease, which typically resolve with skeletal maturity.^{14,63} It is our opinion that PRP is not indicated for these diagnoses. However, a PRP injection can be considered in a skeletally mature adolescent patient with chronic, refractory patellar tendinosis.

Despite the lack of any prospective randomized data to guide our decisions regarding PRP, our clinical indications for PRP treatment for patellar tendinosis are as follows: (1) severe symptoms present for more than 3 months that are unresponsive to physical therapy, (2) clinical findings corroborated by changes on MRI or ultrasound, and (3) the athlete has had a "washout" period from NSAIDs for at least 1 week before PRP injection.⁷³ Additionally, patients are instructed to avoid NSAID use for 3 to 4 weeks after intervention to avoid any interference with muscle healing.⁸⁰ The postinjection protocol includes standard rehabilitation for strength and functional progressions and gradual return to activities over 6 to 8 weeks. Frequent and liberal use of ice, particularly in the early stages, has been helpful in controlling the discomfort that can occur as a result of the injection. Criteria for return to sport include painless full range of motion and ability to tolerate going up and down stairs without discomfort.

Bone Healing

A number of studies have focused on how PRP affects osteoblasts, osteoclasts, and mesenchymal osteoprogenitor stem cells. As mentioned above, it is hypothesized that platelets can act as an exogenous source of growth factors that could potentially stimulate bone formation.¹⁵ Gruber et al⁴¹ showed that platelets can stimulate the formation of osteoclast-like cells, which can help with bone growth and remodeling. Gandhi et al³⁷ investigated the percutaneous application of PRP in a diabetic femur fracture model, suggesting that PRP can upregulate cellular proliferation and improve mechanical strength of the healing bone. Similarly, Sánchez et al⁷⁶ applied PRP to clinical nonunions and reported on their retrospective case series of 16 aseptic supracondylar and diaphyseal atrophic nonunions after failed surgical fixation 21 months previously. Some of these patients were treated with surgical bone grafting augmented by PRP (13 patients) and percutaneous injection of PRP (3 patients). Mixed results were reported and therefore no definitive conclusions could be drawn. The study was further limited by the lack of a control group.⁷⁶ Han et al⁴² recently published an article describing an *in vitro* and *in vivo* experiment to test the effects of PRP as an adjuvant to bone grafting. This study was based on the use of PRP as an autologous source of growth factors that can enhance the quality and quantity of osteogenesis.

The use of PRP to help restore soft tissue or bone defects in different surgical settings, including orthopaedic surgery, maxillofacial surgery, and plastic surgery, has been studied. The use of isolated cells with a biocompatible matrix in combination with PRP maximizes the effects of growth factors on these cells.⁶⁷ The advantage of PRP as a matrix for cells is that PRP is autologous and nontoxic. Therefore, it makes an ideal matrix for cell incubation (eg, mesenchymal cells). Yamada et al⁸⁷ demonstrated in a canine model that the combination of mesenchymal stem

cells with PRP resulted in neovascularization and a higher maturation of bone when compared to the control subjects. Similarly, Kitoh et al⁴⁹ reported on a case series with distraction osteogenesis in which 17 patients were treated with PRP while 29 patients did not receive PRP treatment. The authors concluded that in the PRP group there was no delay in consolidation and there were fewer complications. The role of PRP in bone healing remains an area for fertile research.

Osteoarthritis. Clinical trials are currently underway examining the effects of PRP injection for osteoarthritis of the knee. Kon et al (unpublished data, submitted for publication) have investigated 40 patients with osteoarthritis of the knee who were treated with intra-articular PRP injection. A total of 3 separate injections were administered. Clinical outcome measures revealed significant improvements in visual analog pain scale, International Knee Documentation Committee scores and subjective evaluations at 6-month follow-up ($P < .05$). Specifically, patients under 60 years of age demonstrated 85% satisfaction as opposed to those older than 60 years, who were shown to have 33% satisfaction.

Sánchez et al⁷⁴ also studied the effectiveness of intra-articular injections of PRGF for osteoarthritis of the knee, and performed an observational, retrospective, cohort study using hyaluronan injections for a control group. Each group included 30 patients with osteoarthritis of the knee, matched according to age, sex, body mass index, and radiographic severity. The treatments were based on a total of 3 injections performed over a 3-week period. The observed success rates by week 5 for the pain subscale reached 33.4% for the PRGF group and 10% for the hyaluronan group ($P = .004$). No adverse events were reported.

The interaction of PRP with chondrocytes and growth factors may enable orthopaedic surgeons to improve the current treatment of articular cartilage lesions. The case studies in the literature suggest that there is promise in the treatment of cartilage lesions with PRP or PRP combined with a biomatrix; however, to date, there are no randomized, long-term studies providing reliable medical evidence that supports this claim.

Acute Ligamentous Injuries

Recently, the use of PRP in the treatment of acute ligament injuries in athletes has gained in popularity among sports medicine specialists. After a ligament injury, the medical care of an elite athlete is focused on the safe and expeditious return of the athlete to competition. Medial collateral ligament injuries (of the knee) are a common problem in sports such as soccer and American football. Two of the authors (B.R.M. and M.B.G.) recently completed an unpublished study evaluating a group of professional soccer players with grade II acute medial collateral ligament injuries who were treated with a single PRP injection and were compared to a control group treated with standard rest and rehabilitation. The PRP injections were administered in the intervention group within 72 hours of injury. The return-to-play time was shortened by 27% compared to the control group. This study is limited by its retrospective design and limited number of study participants ($n = 22$).

Acute Muscle Injuries

An injury to muscle tissue can be due to a direct blow, or from tearing of the muscle fibers because of eccentric load while the muscle is contracting. These mechanisms can cause a spectrum of injury ranging from contusion to significant muscle tear (strain). Acute muscle strains are common injuries that account for the majority of missed days of practice and games in the elite athlete.⁴⁴ The most commonly injured muscle groups in the athlete include the hamstrings, gastrocnemius, and quadriceps. These injuries can take several weeks to heal and it is not uncommon for an athlete to miss a significant part of the season depending upon the severity of the injury.

Muscle healing follows the stages of inflammation, proliferation, and remodeling that are coordinated by cellular interactions. As in other parts of the body, healing is dependent upon the vascularity of the tissue.⁸⁸ The speed of recovery depends on the severity of the injury, the postinjury treatment, and the patient's inherent ability to heal soft tissue injuries. The usual recommendation for a muscular injury is rest, ice, compressive dressings, and elevation of the affected extremity. Several techniques have been employed in an effort to shorten return to play intervals.

Platelet-rich plasma has been suggested as a potential intervention for athletes with acute muscular injuries. One *in vitro* study suggests that growth factors may influence muscle regeneration after injury.⁴⁶ Platelet-rich plasma treatment after an acute muscular injury may benefit the athlete by decreasing the time to recovery; however, there are no randomized controlled human studies regarding the use of PRP for muscle injuries.

Cugat et al presented an unpublished case series of 14 professional athletes with acute muscle injuries at the 2005 International Society of Arthroscopy, Knee Surgery, and Orthopaedic Sports Medicine meeting in Florida. This group of athletes included 8 soccer players and 6 basketball players, accounting for a total of 16 muscular injuries. All injuries occurred from direct mechanical trauma and injuries were assigned a grade based on the Rodineau and Durey classification of muscle injuries (grades 1-4, with a higher score corresponding to greater muscle damage).²⁹ An autologous PRP preparation was injected directly into the tear under direct ultrasonic guidance after aspiration of the hematoma. The return-to-play interval was diminished in each group according to severity, and in the less severe injuries (grades 1 and 2), a greater than 50% reduction in return to play was reported. At regular intervals, follow-up included clinical assessment as well as ultrasonic imaging, which confirmed progressive healing of the injured muscle. They concluded that PRP can be helpful in returning athletes to sport, with a shorter time of restoration and rehabilitation. However, the results need to be considered in light of the retrospective nature of the study design. Also, no control group was used. Comparisons were based on previously published expected return-to-play data according to the muscle involved and the injury severity.

Despite the reported success in expediting return to play after muscular injury in the athlete, other researchers have investigated the theoretical concerns that PRP derivatives could induce a fibrotic healing response in muscle tissues.¹⁹ This theoretical deleterious side effect of PRP is

based on the elevation of TGF- β levels after its injection into muscle. Basic science studies have demonstrated that platelet granules can release TGF- β when stimulated (Table 1). Transforming growth factor- β has also been shown to stimulate fibrosis in *in vitro* muscle tissue studies. It is hypothesized that fibrotic healing following muscular injury can lead to an increased incidence of reinjury. Therefore, some researchers have advocated caution when considering PRP injections for athletes with muscular injury. The same group of researchers who raised concerns regarding PRP argue that the introduction of anti-TGF- β agents such as suramin, decorin, γ -interferon, and relaxin may be helpful in reducing fibrosis and thus expediting muscle healing.^{68,69}

Intraoperative Uses of PRP

Total Knee Arthroplasty. The earliest use of PRP in orthopaedic surgery involved total knee arthroplasty (TKA). The primary indication in this setting is to promote wound healing and to decrease blood loss. Berghoff et al¹² reviewed a large series of patients in an attempt to limit blood loss in patients undergoing TKA. The study design included a control group (n = 66) and an intervention group (n = 71). In the intervention group, an autologous PRP fibrin sealant was sprayed in the knee just prior to closure. The PRP was mixed with bovine thrombin and CaCl₂ in an effort to activate the platelets and stimulate the clotting cascade. The intervention group demonstrated higher postoperative hemoglobin levels, lower incidence of postoperative transfusion, and shorter hospital stays. Additionally, at the 6-week follow-up appointment, the intervention group had a significantly greater knee range of motion ($110.2^\circ \pm 9.77^\circ$) compared with the control group ($105.3^\circ \pm 12.1^\circ$) ($P < .05$).

Gardner et al³⁸ conducted a similar study in a series of patients undergoing TKA. In the intervention group, the incision was treated intraoperatively with a platelet gel prior to closure. The authors reported lower blood loss (measured by comparison of preoperative hemoglobin levels to postoperative day 3 hemoglobin), improved early range of motion, and fewer narcotic requirements. However, this was a retrospective chart review, which exposes the study to significant bias.³⁸

Anterior Cruciate Ligament Reconstruction. A series of studies have been performed to evaluate the role of a collagen scaffold containing PRP in anterior cruciate ligament (ACL) healing. There is ineffective healing of ACL tears because of the lack of a bridging scaffold joining the torn ends of the ligament, and due in part to intra-articular fibrinolysates that inhibit formation of a bridging fibrin clot. Application of a collagen hydrogel scaffold containing PRP has been found to improve primary healing of the ACL in several animal models. For instance, in a porcine model of suture repair after ACL transection, ligaments treated with a collagen-PRP hydrogel at the ACL transection site had significant improvement in load at yield, maximum load, and linear stiffness at 4 weeks compared with untreated repairs.⁶⁷ The authors also argue that the collagen-PRP hydrogel improves the healing of direct ACL repair with sutures. In a goat model, the application of a collagen-platelet composite around a patellar tendon

autograft ACL reconstruction resulted in improvements in knee laxity compared to grafts treated with a collagen scaffold alone. There were also significant correlations between serum platelet concentration and anteroposterior laxity ($r^2 = .643$; $P = .009$), maximum load ($r^2 = .691$; $P = .006$), and graft stiffness ($r^2 = .840$; $P < .001$).⁸¹ Presently, there are no in vivo human studies that support the use of PRP with ACL repair or reconstruction.

Acute Achilles Tendon Repair. Sánchez et al⁷⁵ examined the intraoperative use of PRP in athletes undergoing Achilles tendon repair. Platelet-rich plasma was used to augment the primary repair of the Achilles in patients who were compared with age-matched controls. A PRP supernatant was extracted from each patient and then treated in 2 different ways. A CaCl_2 additive was added to 4 mL of PRP and allowed to sit for 30 minutes, allowing the formation of a fibrin type of scaffold. This scaffold was directly incorporated into the Achilles repair. The remaining 4 mL of PRP was treated with CaCl_2 and then immediately sprayed on the repair site just before closure. Follow-up included physical examination and ultrasonic imaging at regular intervals up to a year. The results showed that the intervention group had earlier range of motion, no wound complications, and patients were able to resume gentle running sooner than the control group.

Rotator Cuff Repair. The literature reveals that, despite the technical expertise of the surgeon, a significant failure rate can be expected after rotator cuff repair. The biological milieu at the rotator cuff footprint and the inherent poor healing potential of the distal rotator cuff tendon create an environment that is not optimal for healing of the tendon to bone. Augmentation of the rotator cuff repair with PRP could hypothetically optimize the biologic environment at the repair site, and allow for a more robust healing response at the osseous-tendon interface. The intraoperative use of PRP augmentation of the rotator cuff repair has been gaining in popularity among shoulder surgeons. Gamradt et al²⁶ have reviewed the basic science regarding the use of autogenous platelets and growth factors used to enhance the healing of the repaired rotator cuff. Platelet-rich plasma augmentation of rotator cuff repair at the tendon-bone interface is described in this review. This same group of researchers is currently conducting a randomized clinical trial assessing the efficacy of their described technique.

Acute Articular Cartilage Repair. Articular cartilage injuries and degenerative joint disease represent one of the most challenging and one of the most actively researched topics in all of orthopaedic surgery and sports medicine. Bennett and Schultz¹⁰ showed good results using PRP in treating articular cartilage lesions. Platelet-rich plasma increased total glycosaminoglycosides and type II collagen synthesis with decreased cartilage degradation. Platelet-rich plasma also induced chondrogenesis from mesenchymal stem cells and promoted chondrocyte proliferation, differentiation, and adhesion.¹⁰ Evidence that supports that PRP stimulates mesenchymal stem cells is important because Barry et al⁹ demonstrated that mesenchymal stem cells cultured with TGF- β produced significantly more proteoglycans and type II collagen. Similarly, Fukumoto et al³⁵ found that IGF-I has a synergistic effect with TGF- β in promoting mesenchymal stem cell

chondrogenesis. In addition, Wilke et al⁸⁴ showed early enhanced chondrogenesis in cartilage defects in an equine model and concluded that mesenchymal stem cell arthroscopic implantation in horses improved cartilage healing response.

Cugat et al²¹ described the use of plasma rich in growth factors to treat chondral defects in athletes and reported good results, demonstrating that this plasma in physiological concentrations is effective for the recovery of articular cartilage; furthermore, Cugat et al concluded that local treatment is safe and does not alter the systemic concentrations of these proteins. Anitua et al⁶ demonstrated that platelet-released growth factors induced secretion of hyaluronic acid that may provide a homeostatic environment for tissue repair inside the joint. These studies suggest that PRP may play an important role in cartilage regeneration by regulating cells, protein synthesis, and growth factors.

Akeda et al⁸ showed in a porcine model that PRP plays a role in the upregulation of chondrocytes and cartilage matrix derivatives. Based on their data, clinical researchers have attempted to apply these principles in the clinical setting. For example, Wu et al⁸⁶ suggest that PRP can be used as a chondrocyte carrier for the treatment of acute articular cartilage lesions of the knee. A thrombin-PRP clot served as a scaffold for transferring chondrocytes to the lesion. This concept is offered as a hypothesis, but there are no data regarding outcomes utilizing this technique. Interestingly, Gobbi et al have studied the adjunctive use of PRP and bone marrow cells in the treatment of articular cartilage defects, and gave an oral presentation on these unpublished data at the 2009 International Cartilage Repair Society meeting in Miami. In the presentation, Gobbi described the treatment of 20 patients since 2006 using autologous thrombin and PRP to produce a sticky clot material that is pasted into the defect and then covered with a collagen membrane. The preliminary clinical results are encouraging, with mean International Knee Documentation Committee subjective scores improving from 48.27 preoperatively to 68.58 at 20-month follow-up. The final mean Tegner score of 5.75 was similar to the preinjury score of 6.50, and 92.57 was the final Lysholm score. Within 1 year of the PRP clot placement, a second-look arthroscopy and biopsy was performed. The defect sites were filled with good cartilage-like material that was firm to palpation and a biopsy showed hyaline-like tissue with good integration to the surrounding cartilage.

AUTHORS' CLINICAL EXPERIENCE WITH PRP PREPARATION

Centrifugation Systems

Various plasma separation devices are in active clinical use, and each device has slightly different preparation steps. In general, the process is very straightforward regardless of the manufacturer of the device. The main differences among the current systems include the volume of blood required and the technical handling of the specimen during the centrifugation and separation process. The critical difference among the various systems is in the

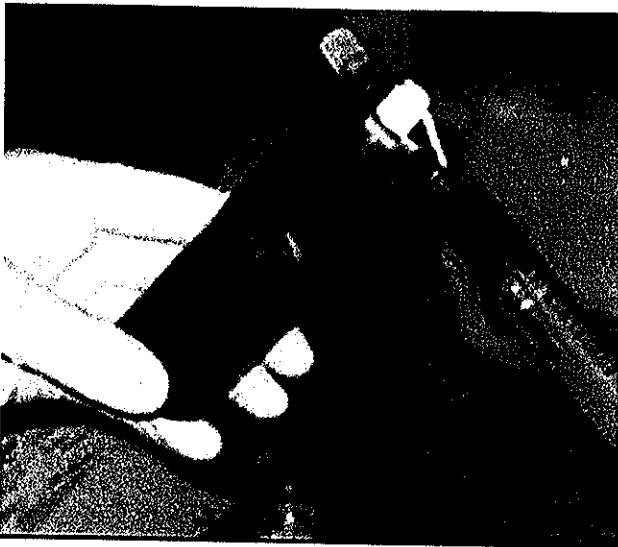


Figure 1. Preparation of platelet-rich layer.

platelet concentration yield. The ideal concentration factor for the platelets is currently unknown, and therefore there does not appear to be any clear-cut superiority of one system over the other at this time.

Harvesting of Cells

The patient's blood is typically drawn from the antecubital region using aseptic technique. It is recommended that an 18-gauge needle be used in an effort to reduce irritation and trauma to the platelets such that they remain in a relative "inactive" state. The blood sample is then transferred to the centrifuge and the spinning process begins. Depending on the system being used, the centrifugation process will ultimately yield between 3 and 6 mL of platelet-rich aggregate (Figure 1) and 30 to 60 mL of whole blood, respectively, may need to be harvested to produce these yields.

Procedure for Soft Tissue Injection

The area of injury is identified and the zone of injury is clearly marked based on physical examination, imaging studies, and area of maximal tenderness. Some clinicians are utilizing dynamic musculoskeletal ultrasound to better identify the area to be injected with PRP. We recommend the use of an ultrasound-guided injection for the treatment of chronic patellar tendinopathy and Achilles tendinopathy because the ultrasound guidance allows for the accurate placement of PRP into the pathologic region of the tendon. There are no data to support the use of ultrasound; however, ultrasound permits the physician to control the depth of the needle and to accurately deliver the PRP into the tendon substance. The use of local anesthetic before injection or with the injection of PRP may be controversial; the anesthetic may change the pH of the tissue and decrease the effectiveness of the injection. This has not been documented clinically, but PRP is sensitive to changes in pH

and local anesthetics may change the tissue environment. A local anesthetic may be delivered prior to injection; the exact timing of the subsequent PRP injection has not been determined. Platelet-rich plasma is delivered via standard injection technique using an 18-gauge needle. Depending on the indication, some clinicians prefer to buffer the PRP with CaCl_2 and thrombin, or the pure sample of PRP can be used. A multiplanar injection technique (peppering the tendon) is recommended in an effort to deliver the platelets to a wider surface area and thus potentially enhance the healing process. Some patients will mount a fairly dramatic inflammatory response after PRP injection, which manifests with discomfort at the injection site. For this reason, we recommend observation for 15 to 20 minutes after injection to make sure the pain is under control and that patients can safely ambulate and function after the procedure. They are instructed to ice the injected area if needed for pain control in addition to elevation of the limb and activity modification for 24 to 48 hours depending on the severity of the injury. Acetaminophen with or without narcotic medication can be taken after the injection for pain control. However, it is important that NSAIDs not be used in the first 2 weeks after injection; they may inhibit the prostaglandin pathway and may inhibit the beneficial effects stimulated by the PRP injection.⁸⁰ There is no current clinical evidence in humans for this practice, but the effect of PRP depends on the inflammatory healing cascade which theoretically could be inhibited by NSAIDs.

DISCUSSION

Platelet-rich plasma has emerged as a promising, but not proven, treatment option for joint, tendon, ligament, and muscle injuries. In vitro basic science studies and in vivo animal studies have helped elucidate some of the effects PRP has on a cellular level to improve tissue repair. Platelet-rich plasma is autologous and able to be administered in a simple fashion, and has an excellent safety profile. Well-designed prospective randomized trials are necessary to better understand the clinical results of PRP treatment.

Regulation of PRP in Sports

The use of PRP in amateur and professional athletes is controversial under the current rules of the antidoping agencies. For instance, an International Olympic Committee Medical Commission Consensus Statement welcomes further research into the area of PRP to understand its therapeutic effects for patient safety.⁵⁵ A 2008 article from the *British Journal of Sports Medicine* commented specifically on the injection of autogenous growth factors that can be found in PRP, and states that World Anti-Doping Agency (WADA) rules prohibit the use of growth hormone, IGF-I, and mechano growth factor (MGF).²⁰ Recently, on September 19, 2009, the WADA Executive Committee addressed the topic of PRP use and decided that platelet-derived preparations will be prohibited when administered by an intramuscular route, and that other routes of administration will require a declaration of use that is in compliance with the

International Standard for Therapeutic Use Exemptions (TUEs). This decision regarding the 2010 Prohibited Substances and Method List will be posted on their official Web site on October 1, 2009, and will take effect on January 1, 2010. Additionally, the US Anti-doping Agency (USADA) has an April 2009 "athlete's advisory" on its official Web site stating that the organization considers a PRP injection equivalent to an injection of growth factors. Consequently, PRP is prohibited under S2 Hormones and Related Substances and an athlete needs a TUE if a medical professional determines that a PRP injection is necessary for an athlete. USADA's position affects all athletes that compete in sports governed by the USADA Protocol for Olympic Movement Testing. It is known that serum IGF-I levels vary greatly among individuals and change depending on a patient's genetics, nutritional status, and how recently they exercised.¹¹ Overall, basic science research supports the belief that PRP is unlikely to provide a potent athletic advantage because unbound IGF-I has too short a half-life (10 minutes to 16 hours) to provide a performance advantage. Isoform IGF-IEa found in PRP is not the isoform responsible for skeletal muscle hypertrophy (IGF-IEc/MGF), and the dose of IGF-I in PRP is subtherapeutic to produce a systemic anabolic effect.²⁰

Olympic-affiliated and international antidoping governing bodies do not have jurisdiction over the professional sports leagues in the United States. Professional baseball, football, soccer, hockey, and basketball are not specifically governed by WADA rules but instead by agreements governed by the provisions of the leagues and unions under their respective collective bargaining agreements. Although these various leagues have a list of banned substances, PRP is not specifically addressed. What remains unclear is whether using PRP, and hence an athlete's own IGF-I, violates antidoping rules, as would the use of an athlete's autologous red blood cells to gain an advantage (blood doping). Throughout the literature, there is no suggestion that PRP has a systemic effect or provides a performance advantage. Additionally, there are only anecdotal reports suggesting that PRP accelerates the repair of an injured area as popularized by the use of PRP to treat the Pittsburgh Steeler Hines Ward's injury before the Super Bowl.⁷⁹

Potential Advantages and Limitations of PRP

If well-controlled clinical trials demonstrate that PRP accelerates the rate of soft tissue injury healing, there are several potential advantages. First, there is a low chance of rejection because the injection is from the patient's autologous blood. Second, PRP can be prepared at the time of care in a simple and relatively inexpensive manner rather than the more complicated process of gathering stem cells.

There are limitations associated with the use of PRP. An optimal dose range of PRP has yet to be defined. Although application of the PRP may enhance mesenchymal stem cell migration and proliferation, overexposure of cells to PRP may also limit differentiation of those cells into the appropriate cell lines.⁶⁰ Thus, there are theoretical concerns that after an injection of PRP, there could be a systemic increase in growth factors and a possible cancer-like effect; but there are no data to support this hypothesis.

Marx⁶⁰ has been critical of this viewpoint as PRP is primarily a patient's own platelets simply administered back to the patient in a more concentrated dose.

A review of the literature reveals a rampant lack of standardization in the preparation of PRP; consequently, it is problematic when attempting to extrapolate data from 1 study to the next. The lack of standardized protocol to produce and evaluate PRP in the literature can help explain the inconsistent clinical and experimental results. Grageda⁴⁰ proposed that in addition to a uniform protocol, future studies should quantify platelet yield both in whole blood and in the PRP used in experiments, and the use of commercial assays to quantify growth factor concentration. To avoid problems in the future, it is imperative to standardize PRP production followed up by a randomized controlled trial to study the effects of PRP on wound healing and promotion of soft tissue and bone healing.

CONCLUSION

It is clear that PRP and PRP-related products have been applied to a diversity of tissues in a variety of surgical fields. The overall goal of PRP is to deliver a high concentration of platelet growth factors to enhance healing. This current review suggests that PRP may be advantageous in sports medicine, but there are little data aside from small case series to support these claims despite PRP's widespread use in the fields of maxillofacial surgery, plastic surgery, and orthopaedic surgery. The use of PRP does have some controversial implications with international antidoping regulations for professional athletes and elite amateur athletes. Multiple basic science, *in vivo* animal, and small human case series agree that PRP has a role in the stimulation of the healing cascade.

The majority of human studies that have been performed have a small number of participants and controls. The studies do not have enough statistical power to document a true statistical difference between the controls and treatment groups. There is a need for prospective, randomized, controlled, double-blind studies that meet the requirements for properly powered studies. The studies need to focus on the use of PRP in the treatment of acute and chronic injuries. The application of PRP in different tissue structures (ligament, tendon, muscle, and articular cartilage) needs to be studied using standardized methods. The appropriate host tissue environment requires further study, and the mechanism of action and clinical effect for each tissue type should be defined.

There remains a significant amount of basic science study and clinical evaluation that is required to define the optimal concentration of PRP, the optimal timing of the injection after an acute injury, and the optimal physiologic environment.

A degree of caution should be exercised with the development of novel technologies. The discovery and subsequent development and use of BMP within orthopaedic surgery also was met with significant optimism regarding its potential clinical application. Thomas A. Einhorn, MD, a thought leader in bone biology and metabolic bone disease, recently said, "The development of BMP definitely rode a wave of optimism that this was the growth factor that was

going to solve all of our bone healing problems. That expectation was not met . . ." (personal communication, TA Einhorn, MD, August 2009). The role of PRP in sports medicine may signal the dawn of a new era in which athletic injuries are treated with cell lines, growth factors, and bioactive proteins, but there remains a significant amount of work before this becomes the standard of care.

REFERENCES

- Adler SC, Kent KJ. Enhancing healing with growth factors. *Facial Plast Surg Clin North Am.* 2002;10(2):129-146.
- Aghaloo TL, Moy PK, Freymiller EG. Evaluation of platelet-rich plasma in combination with freeze-dried bone in rabbit cranium: a pilot study. *Clin Oral Implants Res.* 2005;16(2):250-257.
- Akeda K, An HS, Okuma M, et al. Platelet-rich plasma stimulates porcine articular chondrocyte proliferation and matrix biosynthesis. *Osteoarthritis Cartilage.* 2006;14(12):1272-1280.
- Alfredson H, Lorentzon R. Chronic Achilles tendinosis: recommendations for treatment and prevention. *Sports Med.* 2000;29(2):135-146.
- Alsousou J, Thompson M, Hulley P, Noble A, Willet K. The biology of platelet-rich plasma and its application in trauma and orthopaedic surgery: a review of the literature. *J Bone Joint Surg Br.* 2009;91(8):987-996.
- Anitua E, Sánchez M, Nurden AT, et al. Platelet-released growth factors enhance the secretion of hyaluronic acid and induce hepatocyte growth factor production by synovial fibroblasts from arthritic patients. *Rheumatology (Oxford).* 2007;46(12):1769-1772.
- Aspenberg P, Virchenko O. Platelet concentrate injection improves Achilles tendon repair in rats. *Acta Orthop Scand.* 2004;75(1):93-99.
- Barrett S, Erredge S. Growth factors for chronic plantar fasciitis. *Podiatry Today.* 2004;17:37-42.
- Barry F, Boynton RE, Liu B, Murphy JM. Chondrogenic differentiation of mesenchymal stem cells from bone marrow: differentiation-dependent gene expression of matrix components. *Exp Cell Res.* 2001;268(2):189-200.
- Bennett NT, Schultz GS. Growth factors and wound healing: biochemical properties of growth factors and their receptors. *Am J Surg.* 1993;165(6):728-737.
- Berg U, Bang P. Exercise and circulating insulin-like growth factor-1. *Horm Res.* 2004;62(Suppl 1):50-58.
- Berghoff W, Pietrzak W, Rhodes R. Platelet-rich plasma application during closure following total knee arthroplasty. *Orthopedics.* 2006;29(7):590-598.
- Bhanot S, Alex JC. Current application of platelet gels in facial plastic surgery. *Facial Plast Surg.* 2002;18(1):27-33.
- Blazina ME, Kerlan RK, Jobe FW, Carter VS, Carlson GJ. Jumper's knee. *Orthop Clin North Am.* 1973;4(3):665-678.
- Bolander ME. Regulation of fracture repair by growth factors. *Proc Soc Exp Biol Med.* 1992;200:165-170.
- Camargo PM, Lekovic V, Weinlaender M, Vasilic N, Madzarevic M, Kenney EB. Platelet rich plasma and bovine porous bone mineral combined with guided tissue regeneration in the treatment of intra-bony defects in humans. *J Periodont Res.* 2002;37(4):300-306.
- Carreon LY, Glassman SD, Anekstein Y, Puno RM. Platelet gel (AGF) fails to increase fusion rates in instrumented posterolateral fusions. *Spine (Phila Pa 1976).* 2005;30(9):E243-E247.
- Carroll RJ, Arnoczky SP, Graham S, O'Connell SM. *Characterization of Autologous Growth Factors. Cascade® Platelet-Rich Fibrin Matrix (PRFM).* Edison, NJ: Musculoskeletal Transplant Foundation; 2005.
- Chan YS, Li Y, Foster W, Fu FH, Huard J. The use of suramin, an antifibrotic agent to improve muscle recovery after strain injury. *Am J Sports Med.* 2005;33:43-51.
- Creaney L, Hamilton B. Growth factor delivery methods in the management of sports injuries: state of play. *Br J Sports Med.* 2008;42(5):314-320.
- Cugat R, Carrillo JM, Serra I, Soler C. Articular cartilage defects reconstruction by plasma rich in growth factors. In: Brittberg M, Marcacci M, Zanasi S, eds. *Basic Science, Clinical Repair and Reconstruction of Articular Cartilage Defects: Current Status and Prospects.* Bologna, Italy: Timeo Editore; 2006:801-807.
- Dallari D, Savarino L, Stagni C, et al. Enhanced tibial osteotomy healing with use of bone grafts supplemented with platelet gel or platelet gel and bone marrow stromal cells. *J Bone Joint Surg Am.* 2007;89(11):2413-2420.
- Danesh-Meyer MJ, Filstein MR, Shanaman R. Histological evaluation of sinus augmentation using platelet rich plasma (PRP): a case series. *J Int Acad Periodontol.* 2001;3(2):48-56.
- Deirossi AJ, Cernaianu AC, Vertrees RA, et al. Platelet-rich plasma reduces postoperative blood loss. *J Thorac Cardiovasc Surg.* 1990;100(2):281-286.
- de Mos M, van der Windt AE, Jahr H, van Schie HT, Weinans H, Verhaar JA, van Osch GJ. Can platelet-rich plasma enhance tendon repair? A cell culture study. *Am J Sports Med.* 2008;36(6):1171-1178.
- Edwards SG, Calandruccio JH. Autologous blood injection for refractory lateral epicondylitis. *J Hand Surg [Am].* 2003;28(2):272-278.
- El-Khoury GY, Wira RL, Berbaum KS, Pope TL Jr, Monu JU. MR imaging of patellar tendinitis. *Radiology.* 1992;184(3):849-854.
- Eppley BL, Pietrzak WS, Blanton M. Platelet rich plasma: a review of biology and applications in plastic surgery. *Plast Reconstr Surg.* 2006;118(6):147e-159e.
- Espregueira-Mendes J, Arce C. Referee lesions. In: Volpi P, ed. *Football Traumatology: Current Concepts: From Prevention to Treatment.* Milan, Italy: Springer 2006:92.
- Everts PA, Devilee RJ, Brown Mahoney C, et al. Platelet gel and fibrin sealant reduce allogenic blood transfusions in total knee arthroplasty. *Acta Anaesthesiol Scand.* 2006;50(5):593-599.
- Ferretti A, Ippolito E, Mariani P, Puddu G. Jumper's knee. *Am J Sports Med.* 1983;11(2):58-62.
- Fritschy D, de Gautard R. Jumper's knee and ultrasonography. *Am J Sports Med.* 1988;16(6):637-640.
- Froun SJ, Wallace SS, Tarnow DP, Cho SC. Effect of platelet rich plasma on bone growth and osseointegration in human maxillary sinus grafts: three bilateral case reports. *Int J Periodont Restor Dent.* 2002;22(1):45-53.
- Fufa D, Shealy B, Jacobson M, Kevy S, Murray MM. Activation of platelet-rich plasma using soluble type I collagen. *J Oral Maxillofac Surg.* 2008;66(4):684-690.
- Fukumoto T, Sperling JW, Sanyal A, et al. Combined effects of insulin-like growth factor-1 and transforming growth factor-beta1 on periosteal mesenchymal cells during chondrogenesis in vitro. *Osteoarthritis Cartilage.* 2003;11(1):55-64.
- Gamradt SC, Rodeo SA, Warren RF. Platelet rich plasma in rotator cuff repair. *Techniques in Orthopaedics.* 2007;22:26-33.
- Gandhi A, Doumas C, O'Connor JP, Parsons JR, Lin SS. The effects of local platelet rich plasma delivery on diabetic fracture healing. *Bone.* 2006;38:540-546.
- Gardner MJ, Demetropoulos D, Klepchick P, Moar P. The efficacy of autologous platelet gel in pain control and blood loss in TKR: an analysis of the haemoglobin, narcotic requirement and range of motion. *Int Orthop.* 2007;31:309-313.
- Garg AK. The use of platelet rich plasma to enhance the success of bone grafts around dental implants. *Dent Implantol Update.* 2000;11(3):17-21.
- Grageda E. Platelet-rich plasma and bone graft materials: a review and a standardized research protocol. *Implant Dent.* 2004;13:301-309.
- Gruber R, Karreth F, Fischer ME, Watzek G. Platelet released supernatants stimulate formation of osteoclast-like cells through a prostaglandin/RANKL dependent mechanism. *Bone.* 2002;30:726-732.
- Han B, Woodell-May J, Ponticciello M, Yang Z, Nimmi M. The effect of thrombin activation of platelet-rich plasma on demineralized bone matrix osteoconductivity. *J Bone Joint Surg Am.* 2009;91(6):1459-1470.
- Hiramatsu T, Okamura T, Imai Y, et al. Effects of autologous platelet concentrate reinfusion after open heart surgery in patients with congenital heart disease. *Ann Thorac Surg.* 2002;73(4):1282-1285.
- Junge A, Dvorak J, Graf-Baumann T. Football injuries during World Cup 2002. *Am J Sports Med.* 2004;32(1 Suppl):23S-27S.
- Kajikawa Y, Morihara T, Sakamoto H, et al. Platelet-rich plasma enhances the initial mobilization of circulation-derived cells for tendon healing. *J Cell Physiol.* 2008;215(3):837-845.

46. Kasemkijwattana C, Menetrey J, Bosch P, et al. Use of growth factors to improve muscle healing after strain injury. *Clin Orthop Relat Res.* 2000;370:272-285.
47. Kassolis JD, Rosen PS, Reynolds MA. Alveolar ridge and sinus augmentation utilizing platelet rich plasma in combination with freeze-dried bone allograft: case series. *J Periodontol.* 2000;71(10):1654-1661.
48. Kim SG, Chung CH, Kim YK, Park JC, Lim SC. Use of particulate dentin-plaster of Paris combination with/without platelet rich plasma in the treatment of bone defects around implants. *Int J Oral Maxillofac Implant.* 2002;17(1):86-94.
49. Kitoh H, Kitakoji T, Tsuchiya H, Katoh M, Ishiguro N. Transplantation of culture expanded bone marrow cells and platelet rich plasma in distraction osteogenesis of the long bones. *Bone.* 2007;40(2):522-528.
50. Knighton DR, Ciresi KF, Fiegel VD, Austin LL, Butler EL. Classification and treatment of chronic nonhealing wounds: successful treatment with autologous platelet-derived wound healing factors (PDWHF). *Ann Surg.* 1986;204(3):322-330.
51. Krijgsveld J, Zaat SA, Meeldijk J, et al. Thrombocidins, microbicidal proteins from human blood platelets, are C-terminal deletion products of CXC chemokines. *J Biol Chem.* 2000;275(27):20374-20381.
52. Krivickas LS. Anatomical factors associated with overuse sports injuries. *Sports Med.* 1997;24(2):132-146.
53. Kvist M, Józsa L, Järvinen MJ, Kvist H. Chronic Achilles paratenonitis: a histological and histochemical study. *Pathology.* 1987;19(1):1-11.
54. Liu Y, Kalén A, Risto O, Wahlström O. Fibroblast proliferation due to exposure to a platelet concentrate in vitro is pH dependent. *Wound Repair Regen.* 2002;10(5):336-340.
55. Ljungqvist A, Schwelnuus MP, Bachl N, et al. International Olympic Committee consensus statement: Molecular basis of connective tissue and muscle injuries in sport. *Clin Sports Med.* 2008;27(1):231-239, x-xi.
56. Los G, De Weger RA, Van den Berg DT, Sakkars R, Den Otter W. Macrophage infiltration in tumors and tumor-surrounding tissue: influence of serotonin and sensitized lymphocytes. *Cancer Immunol Immunother.* 1988;26(2):145-152.
57. Lucarelli E, Beccheroni A, Donati D, et al. Platelet-derived growth factors enhance proliferation of human stromal stem cells. *Biomaterials.* 2003;24(18):3095-3100.
58. Man D, Plosker H, Winland-Brown JE. The use of autologous platelet rich plasma (platelet gel) and autologous platelet poor plasma (fibrin glue) in cosmetic surgery. *Plast Reconstr Surg.* 2001;107(1):229-239.
59. Mandel MA. Minimal suture blepharoplasty: closure of incisions with autologous fibrin glue. *Aesthetic Plast Surg.* 1992;16:269-272.
60. Marx RE. Platelet-rich plasma: evidence to support its use. *J Oral Maxillofac Surg.* 2004;62:489-496.
61. Marx RE. Platelet-rich plasma (PRP): what is PRP and what is not PRP? *Implant Dent.* 2001;10(4):225-228.
62. Marx RE, Carlson ER, Eichstaedt RM, Schimmele SR, Strauss JE, Georgeff KR. Platelet-rich plasma: growth factor enhancement for bone grafts. *Oral Surg Oral Med Oral Pathol Oral Radiol Endod.* 1998;85(6):638-646.
63. Medlar RC, Lyne ED. Sinding-Larsen-Johansson disease: its etiology and natural history. *J Bone Joint Surg Am.* 1978;60(8):1113-1116.
64. Mehta S, Watson JT. Platelet-rich concentrate: basic science and clinical applications. *J Orthop Trauma.* 2008;22(6):432-438.
65. Menetrey J, Kasemkijwattana C, Day CS, et al. Growth factors improve muscle healing in vivo. *J Bone Joint Surg Br.* 2000;82(1):131-137.
66. Mishra A, Pavelko T. Treatment of chronic elbow tendinosis with buffered platelet-rich plasma. *Am J Sports Med.* 2006;34(11):1774-1778.
67. Murray MM, Spindler KP, Abreu E, et al. Collagen-platelet rich plasma hydrogel enhances primary repair of the porcine anterior cruciate ligament. *J Orthop Res.* 2007;25(1):81-91.
68. Negishi S, Li Y, Usas A, Fu FH, Huard J. The effect of relaxin treatment on skeletal muscle injuries. *Am J Sports Med.* 2005;33:1816-1824.
69. Nozaki M, Li Y, Zhu J, et al. Improved muscle healing after contusion injury by the inhibitory effect of suramin on myostatin, a negative regulator of muscle growth. *Am J Sports Med.* 2008;36:2354-2362.
70. Popp JE, Yu JS, Kaeding CC. Recalcitrant patellar tendinitis: magnetic resonance imaging, histologic evaluation, and surgical treatment. *Am J Sports Med.* 1997;25(2):218-222.
71. Puddu G, Ippolito E, Postacchini F. A classification of Achilles tendon disease. *Am J Sports Med.* 1976;4(4):145-150.
72. Raghoobar GM, Schortinghuis J, Liem RS, Ruben JL, van der Wal JE, Vissink A. Does platelet-rich plasma promote remodeling of autologous bone grafts used for augmentation of the maxillary sinus floor? *Clin Oral Implants Res.* 2005;16:349-356.
73. Sampson S, Gerhardt M, Mandelbaum B. Platelet rich plasma injection grafts for musculoskeletal injuries: a review. *Curr Rev Musculoskeletal Med.* 2008;1(3-4):165-174.
74. Sánchez M, Anitua E, Azofra J, Aguirre JJ, Andia I. Intra-articular injection of an autologous preparation rich in growth factors for the treatment of knee OA: a retrospective cohort study. *Clin Exp Rheumatol.* 2008;26(5):910-913.
75. Sánchez M, Anitua E, Azofra J, Andia I, Padilla S, Mujika I. Comparison of surgically repaired Achilles tendon tears using platelet-rich fibrin matrices. *Am J Sports Med.* 2007;35(2):245-251.
76. Sánchez M, Anitua E, Cugat R, et al. Nonunions treated with autologous preparation rich in growth factors. *J Orthop Trauma.* 2009;23(1):52-59.
77. Savarino L, Cenni E, Tarabusi C, et al. Evaluation of bone healing enhancement by lyophilized bone grafts supplemented with platelet gel: a standardized methodology in patients with tibial osteotomy for genu varus. *J Biomed Mater Res B Appl Biomater.* 2006;76(2):364-372.
78. Schnabel LV, Mohammed HO, Miller BJ, et al. Platelet rich plasma (PRP) enhances anabolic gene expression patterns in flexor digitorum superficialis tendons. *J Orthop Res.* 2007;25(2):230-240.
79. Schwartz A. A promising treatment for athletes, in blood. *The New York Times.* February 17, 2009. Available at <http://www.nytimes.com/2009/02/17/sports/17blood.html?scp=1&sq=platelet%20rich%20plasma%20and%20pittsburgh&st=cse>.
80. Shen W, Li Y, Tang Y, Cummins J, Huard J. NS-398, a cyclooxygenase-2-specific inhibitor, delays skeletal muscle healing by decreasing regeneration and promoting fibrosis. *Am J Pathol.* 2005;167(4):1105-1117.
81. Spindler KP, Murray MM, Carey JL, Zurakowski D, Fleming BC. The use of platelets to affect functional healing of an anterior cruciate ligament (ACL) autograft in a caprine ACL reconstruction model. *J Orthop Res.* 2009;27(5):631-638.
82. Tayapongsak P, O'Brien DA, Monteiro CB, Arceo-Diaz LY. Autologous fibrin adhesive in mandibular reconstruction with particulate cancellous bone and marrow. *J Oral Maxillofac Surg.* 1994;52:161-165.
83. Taylor MA, Norman TL, Clovis NB, Blaha JD. The response of rabbit patellar tendons after autologous blood injection. *Med Sci Sports Exerc.* 2002;34(1):70-73.
84. Wilke MM, Nydam DV, Nixon AJ. Enhanced early chondrogenesis in articular defects following arthroscopic mesenchymal stem cell implantation in an equine model. *J Orthop Res.* 2007;25(7):913-925.
85. Wright-Carpenter T, Opolon P, Appell HJ, Meijer H, Wehling P, Mir LM. Treatment of muscle injuries by local administration of autologous conditioned serum: animal experiments using a muscle contusion model. *Int J Sports Med.* 2004;25(8):582-587.
86. Wu W, Zhang J, Dong Q, Liu Y, Mao T, Chen F. Platelet-rich plasma: a promising cell carrier for micro-invasive articular cartilage repair. *Med Hypotheses.* 2009;72(4):455-457.
87. Yamada Y, Ueda M, Naiki T, Takahashi M, Hata K, Nagasaka T. Autogenous injectable bone for regeneration with mesenchymal stem cells and platelet-rich plasma: tissue-engineered bone regeneration. *Tissue Eng.* 2004;10:955-964.
88. Yokota K, Ishida O, Sunagawa T, Suzuki O, Nakamae A, Ochi M. Platelet-rich plasma accelerated surgical angiogenesis in vascular-implanted necrotic bone: an experimental study in rabbits. *Acta Orthop.* 2008;79(1):106-110.

Platelet-rich Plasma: Current Concepts and Application in Sports Medicine

Michael P. Hall, MD, Phillip A. Band, PhD, Robert J. Meislin, MD, Laith M. Jazrawi, MD, Dennis A. Cardone, DO

J Am Acad Orthop Surg 2009;17: 602-608

ENTORNO

El plasma rico en plaquetas (PRP) es un concentrado plaquetario procedente de la sangre del paciente. Desde su utilización en cirugía maxilofacial y plástica en la década de los 90, su uso en cirugía deportiva ha ido en aumento para acelerar la recuperación de músculos y tendones.

PREPARACIÓN

La muestra de sangre es anticoagulada y centrifugada para aislar las plaquetas. Tras su obtención, el PRP puede ser administrado con o sin agentes activadores. Su combinación con cloruro de calcio y/o trombina justo antes de su inyección inicia la activación plaquetaria, formación del coágulo y liberación de los factores de crecimiento en el punto de inyección. La utilización de PRP sin un activador exógeno es también una práctica común, con evidencia demostrada de que las plaquetas se activarán al contactar con el colágeno de los tendones.

Sistema	Volumen de Sangre	tiempo/RPM	Volumen final de PRP	Concentración plaquetaria	Activador
Autologous Conditioned Plasma (Arthrex)	9	5min/1500	3-5ml	2-3X	ninguno
Cascade (Musculoskeletal Tissue Foundation,)	9 ó 18	1º: 6 min/1,100; 2º: 15min/1450	2 ó 4	ND	Calcio
GPS III (Biomet)	27 ó 54	15 min/1900	3 ó 6	4-8X	Cloruro cálcico/trombina
SmartPREP (Harvest Technologies)	20-60	14 min/1000	3 ó 7	4,4-7,6X	Trombina

Existen controversias acerca de la cantidad óptima de plaquetas y factores de crecimiento para obtener la recuperación de músculos y tendones deseada. El PRP clínicamente eficaz se ha definido como aquel cuya concentración de plaquetas es cuatro veces superior al de la sangre. Sin embargo la eficacia del PRP ha sido demostrada con preparaciones con una menor concentración.

EVIDENCIA

- *In vitro*, el PRP aumenta la concentración de factores de crecimiento, estimula la síntesis de colágeno, promueve la angiogénesis y la proliferación celular.
- En la clínica, el PRP ha mostrado su eficacia en el tratamiento de epicondilitis en el codo, tendinosis patelar crónica, fascitis plantar y lesiones musculares. Además, la aplicación intraoperatoria de PRP en cirugías de tendón de Aquiles, reparación por artroscopia del manguito de los rotadores y reconstrucción del ligamento cruzado anterior, mejora la función motora, disminuye el dolor, la necesidad de analgésicos, y acelera la recuperación.